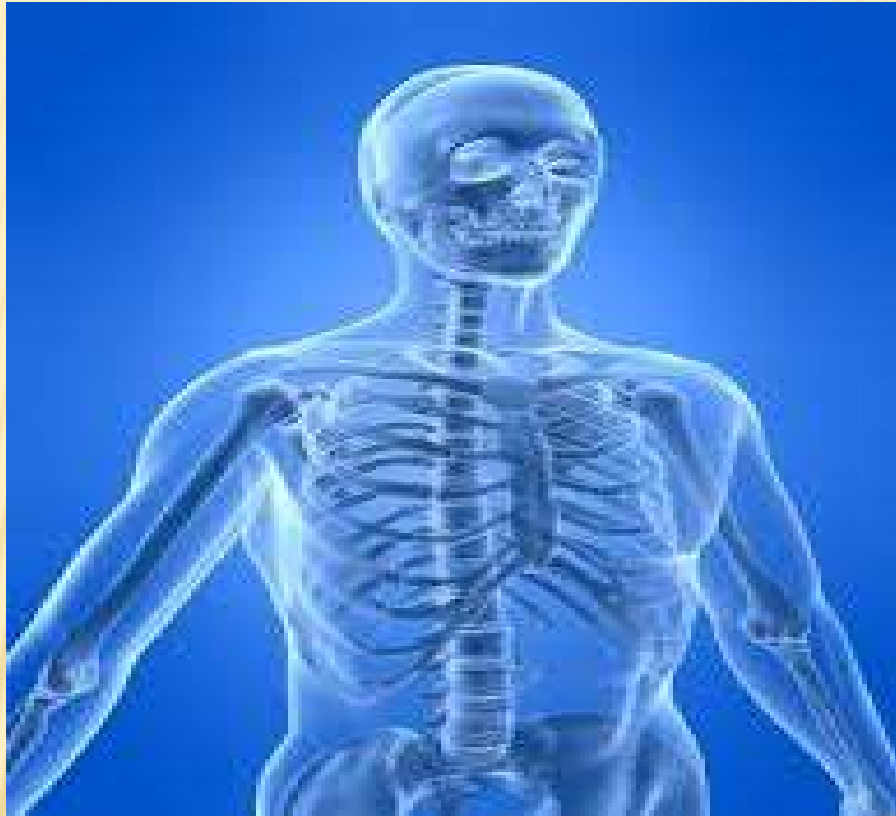

Skeletal System

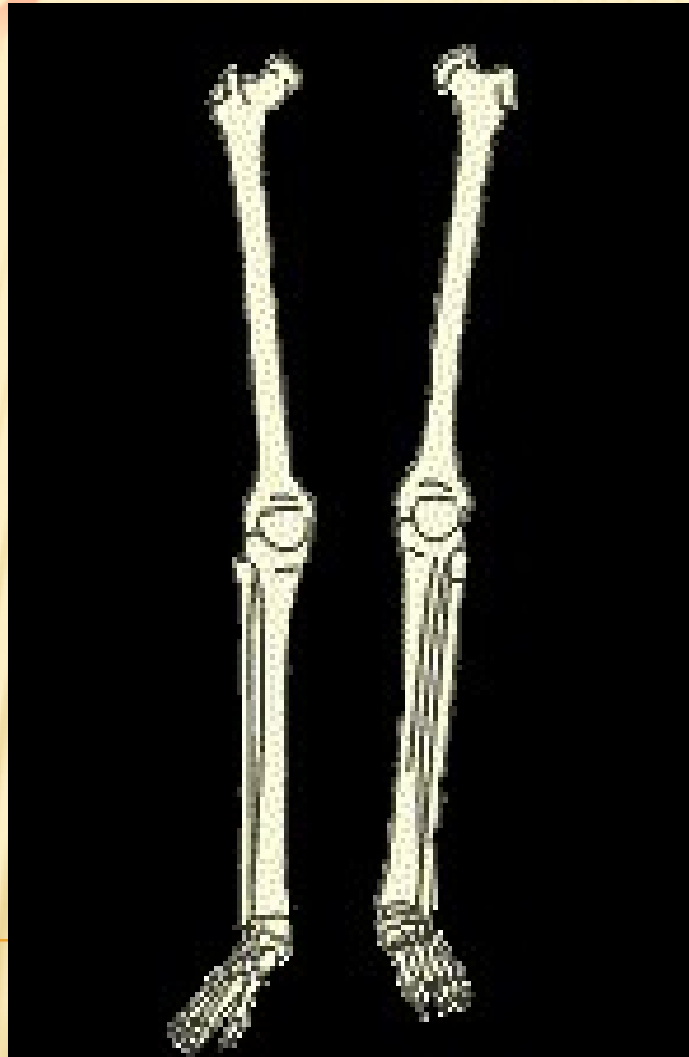


BY
DR. AVIJEET MONDAL

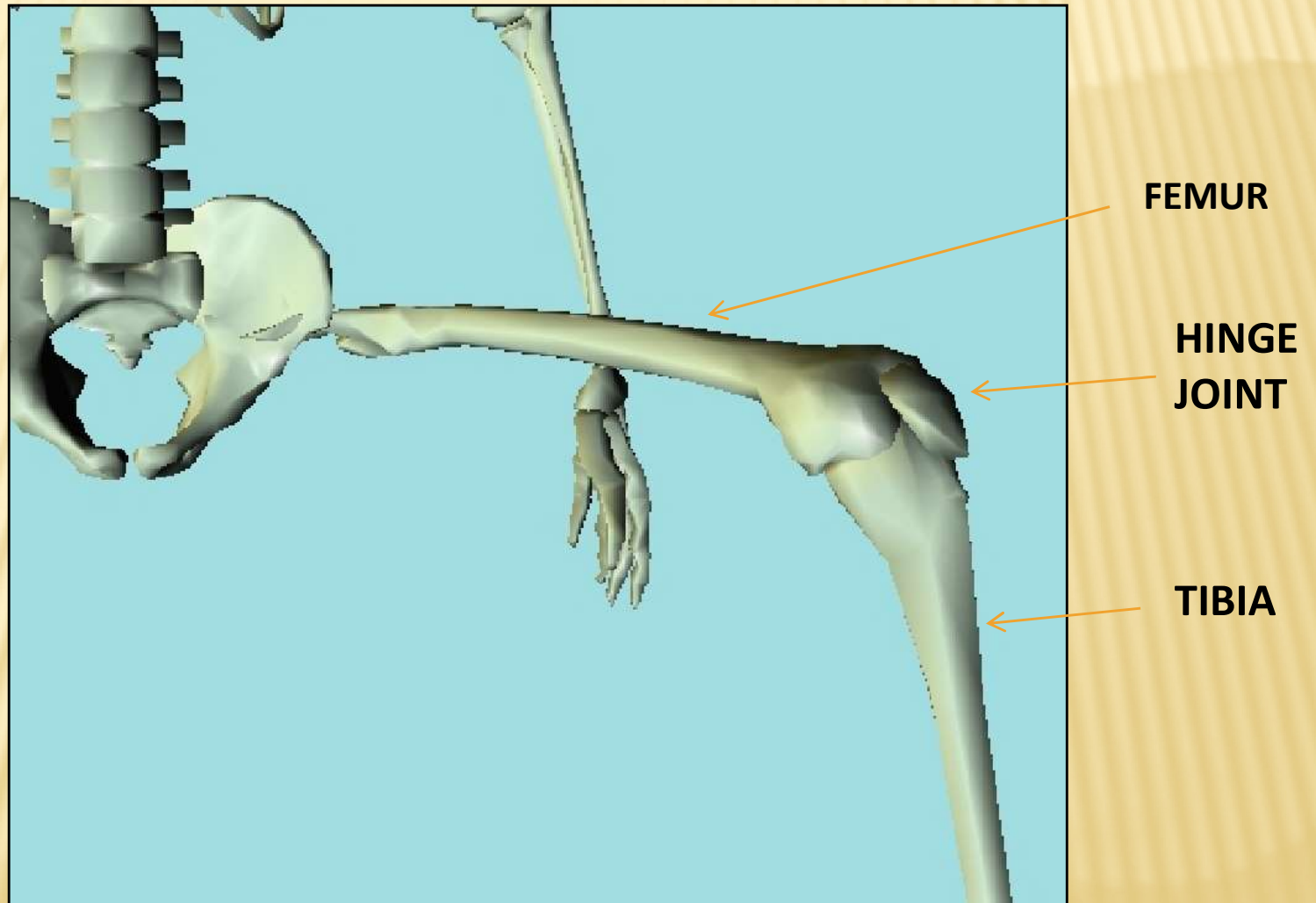
Skeletal system consist of

- Bones
- Joints
- Cartilages
- Ligaments

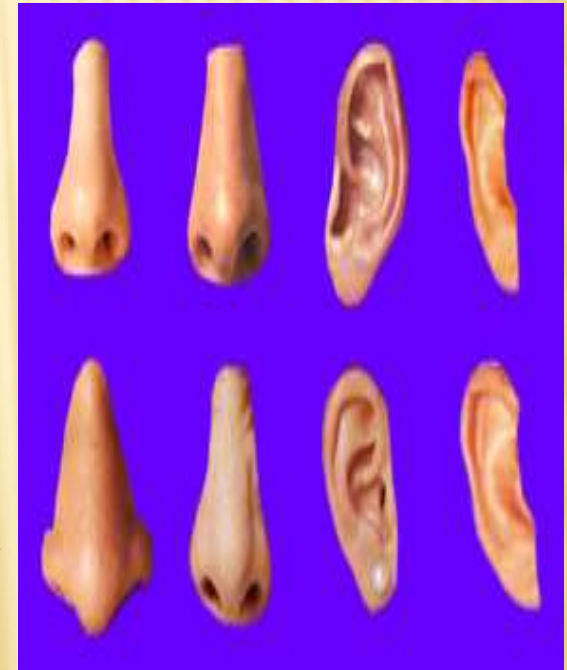
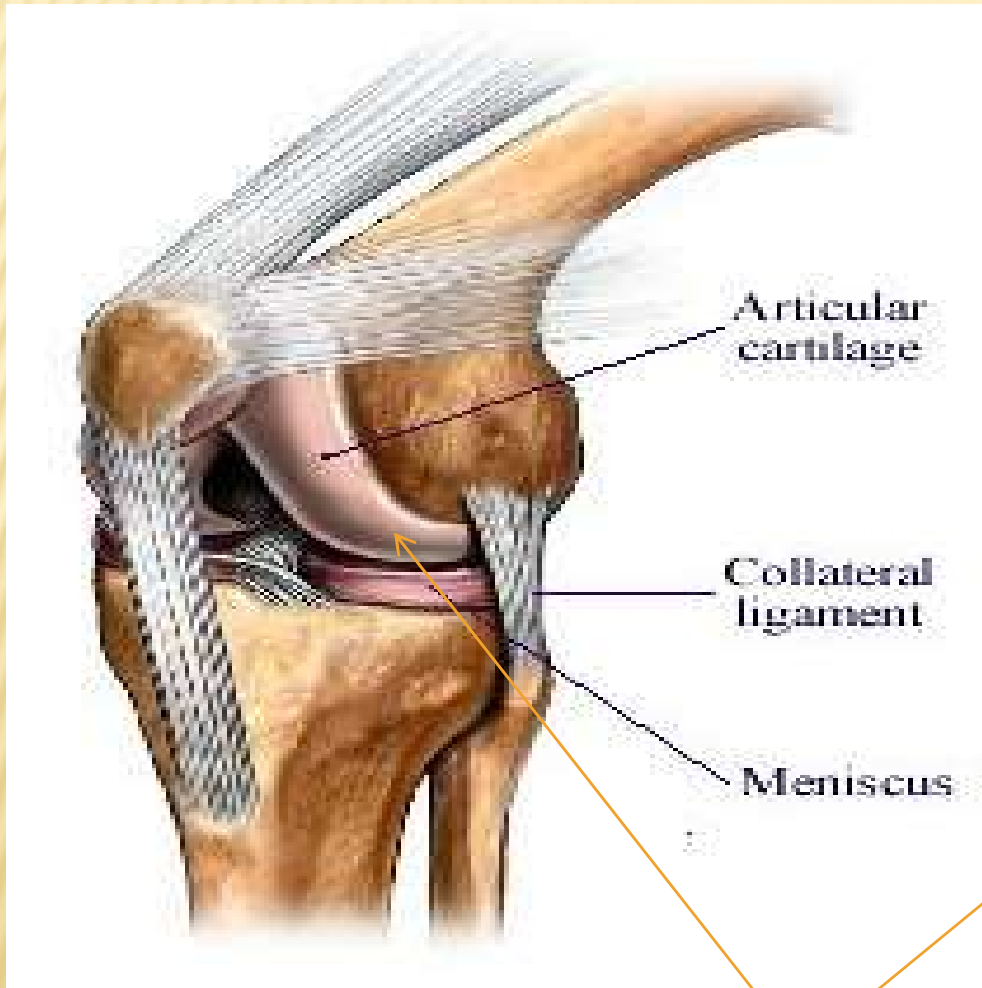
BONES



JOINTS



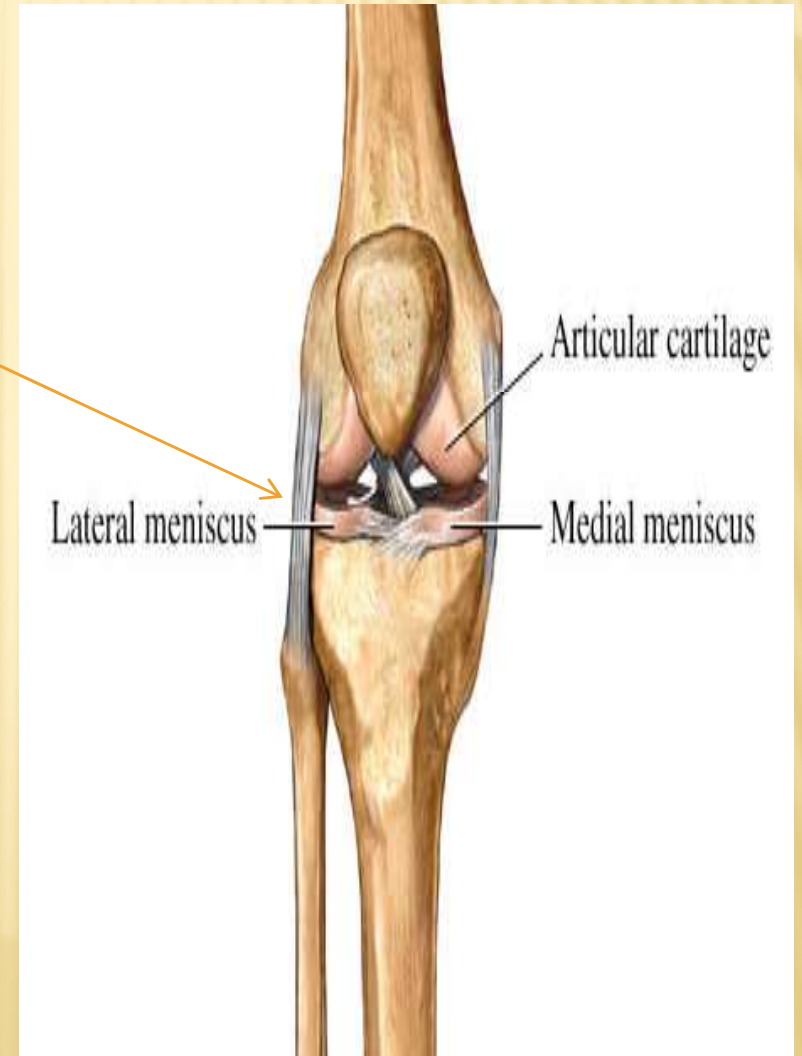
Cartilage



Cartilage

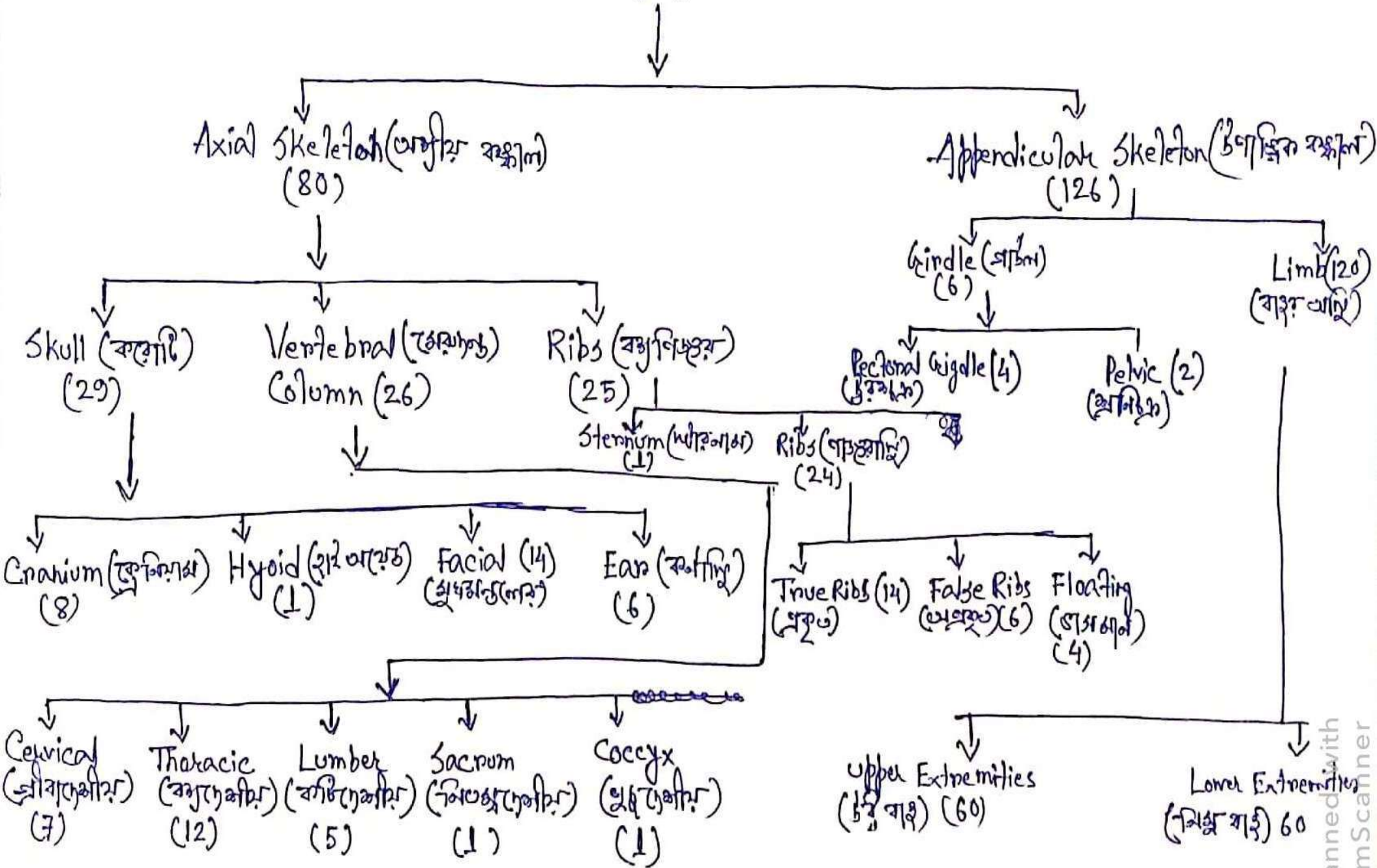
Ligaments

Connect bone to bone

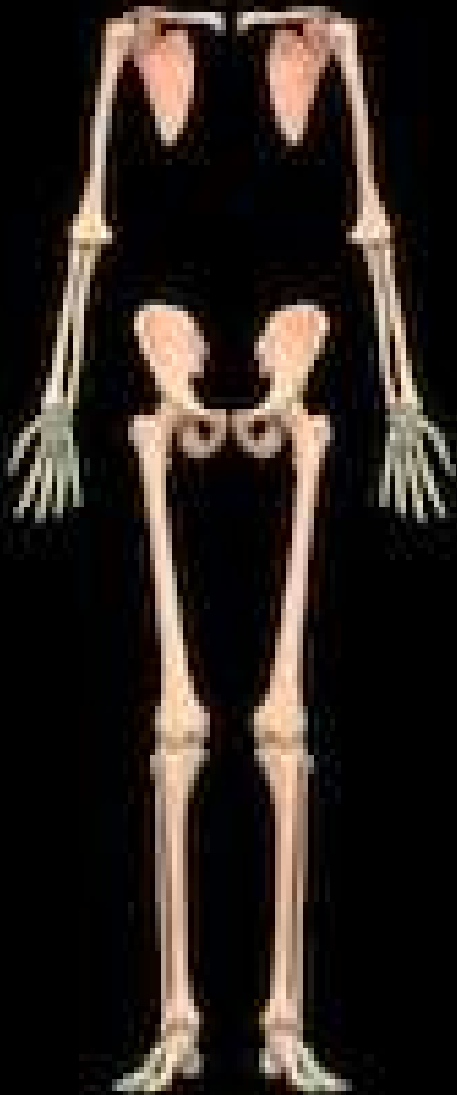

Skeletal System (বাস্তবিক সিস্টেম)

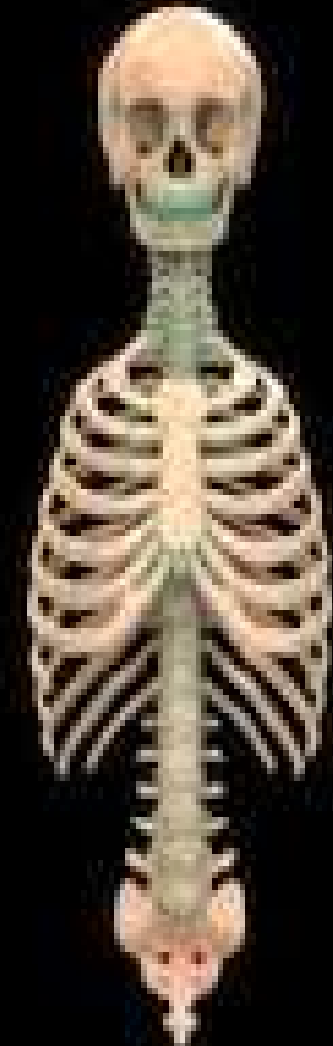
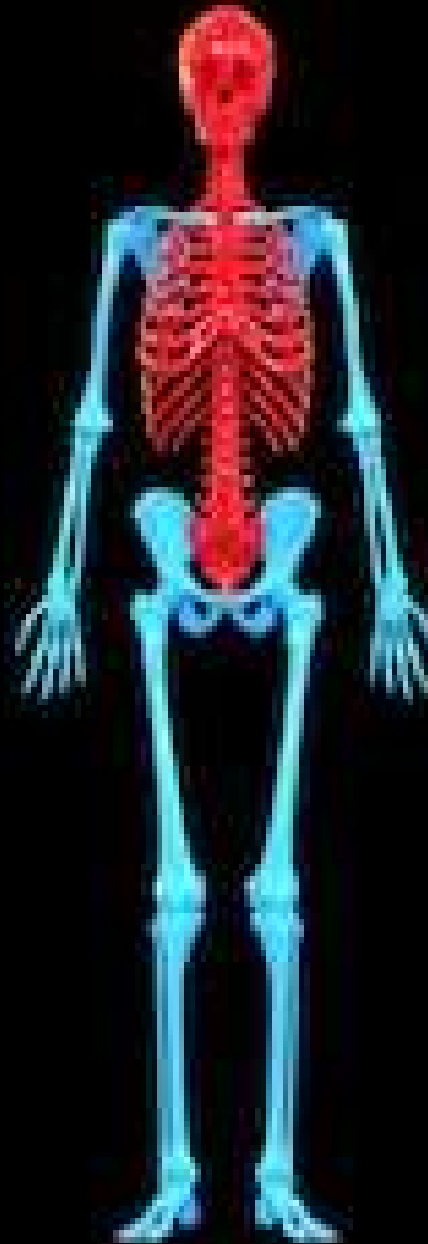(206)



Human Skeleton System Anatomy



Appendicular Skeleton



Axial Skeleton

AXIAL SKELETON

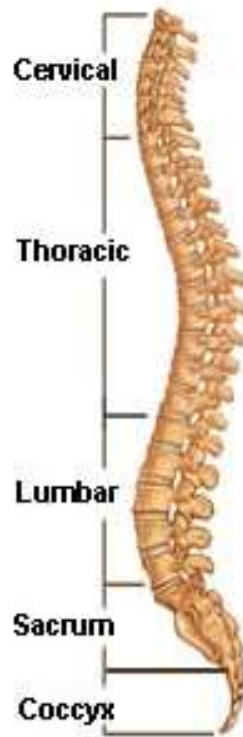
SKULL

VERTEBRAL COLUMN

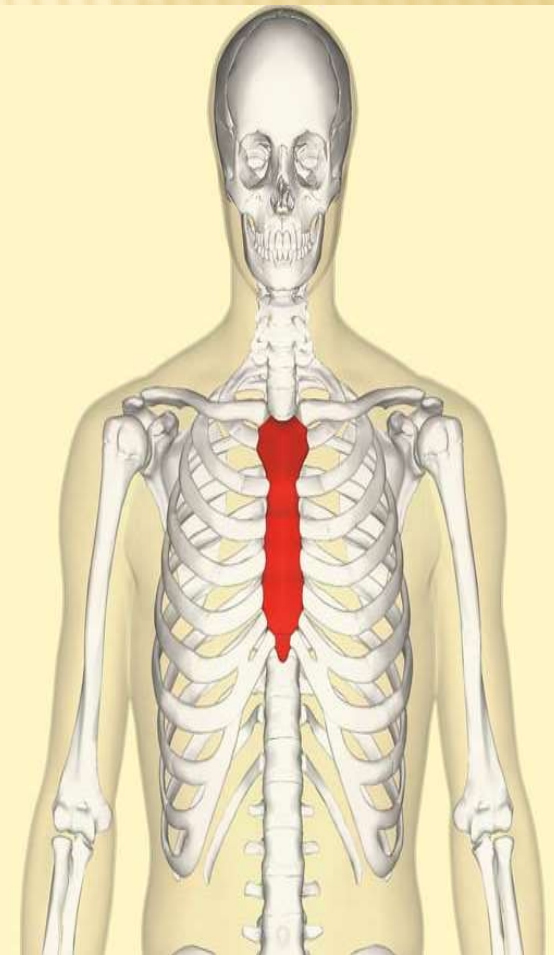
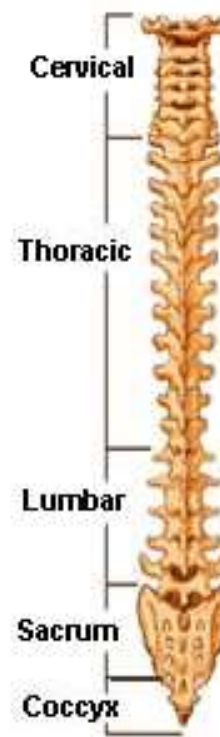
RIBS



Lateral (Side)
Spinal Column



Posterior (Back)
Spinal Column



SKULL



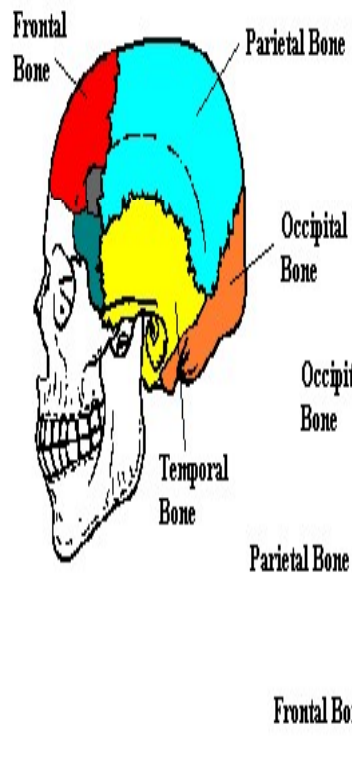
CRANIUM BONE

FACIAL BONE

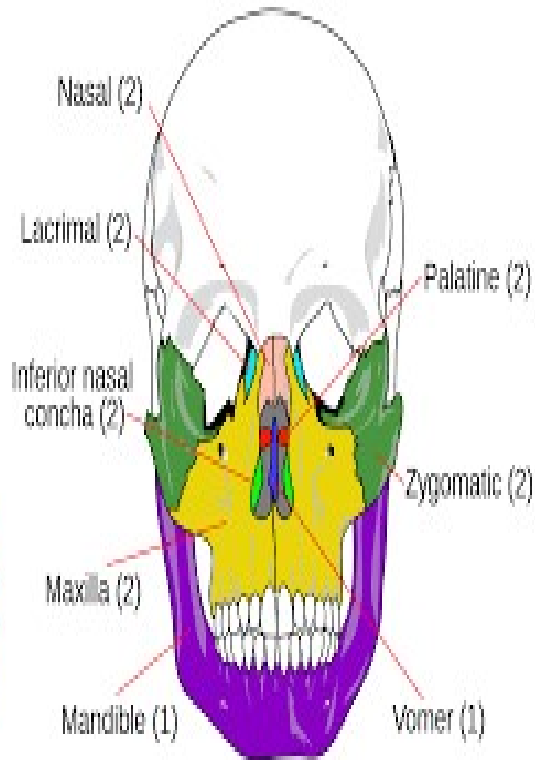
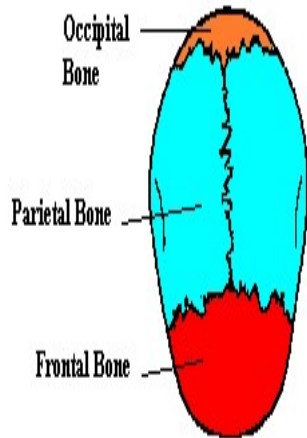
HYOID BONE

EAR BONE

Side View



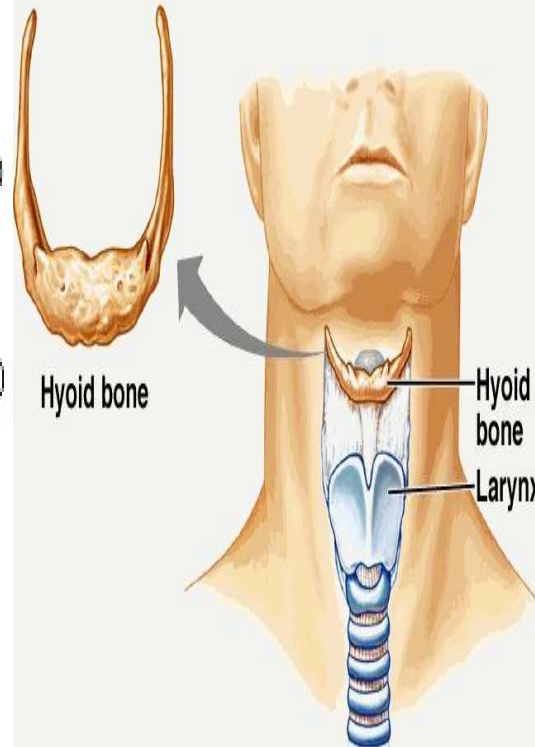
Top View



14 facial bones

Copyright © The McGraw-Hill Companies, Inc. Permission required for reproduction or display.

Hyoid Bone

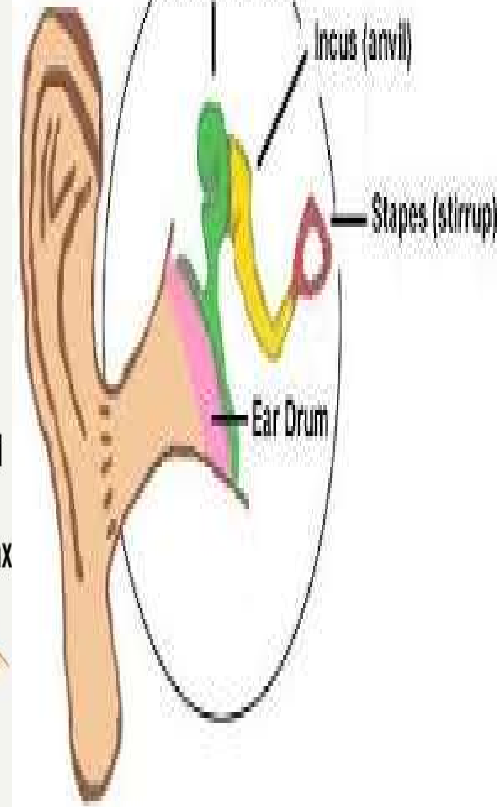


Malleus (hammer)

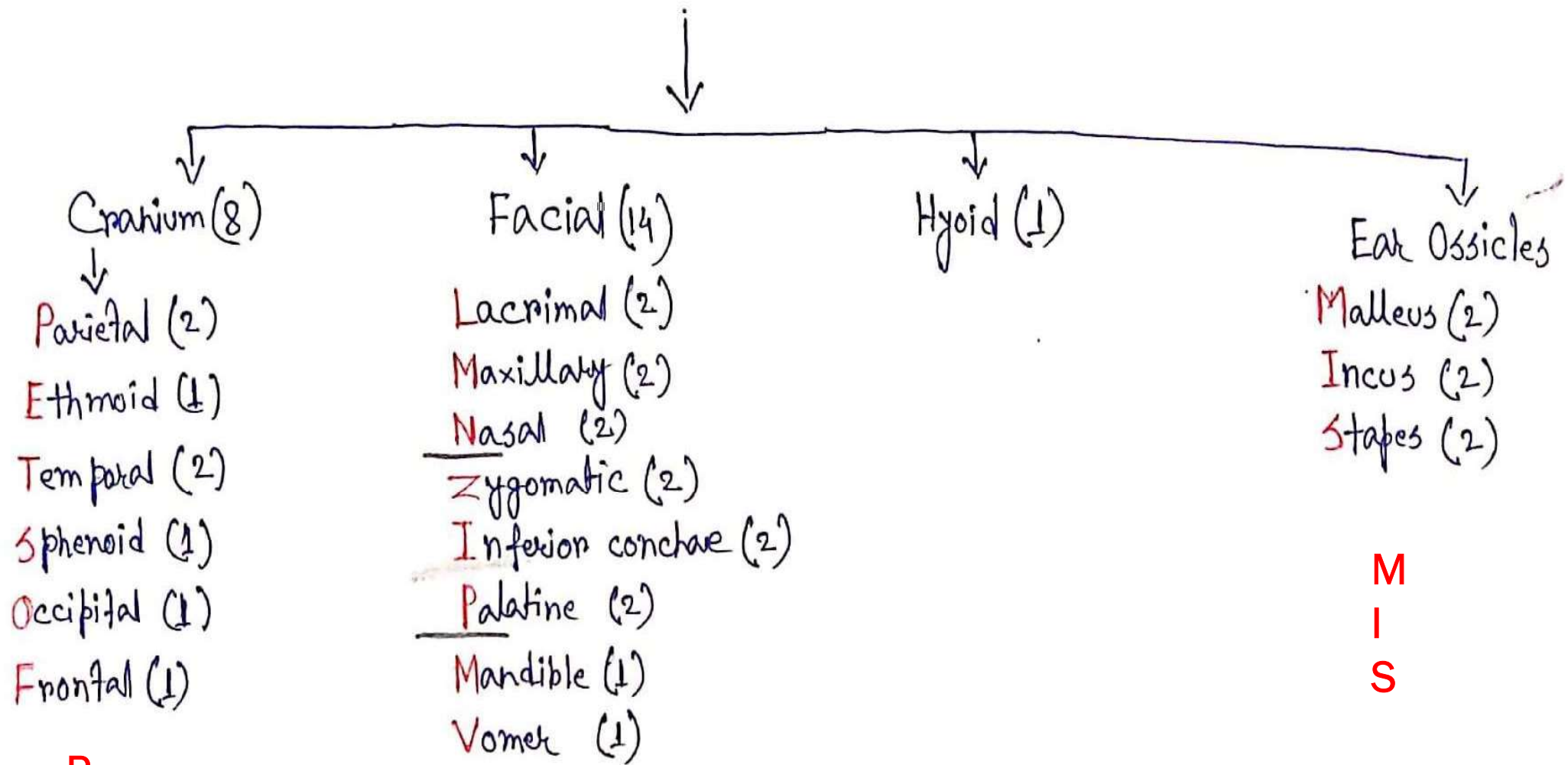
Incus (anvil)

Stapes (stirrup)

Ear Drum



Skull (29)



P
E
T
S
O
F

LMN - ZIP - MV

M
I
S